

Does routine surveillance imaging after completing treatment for childhood extra-cranial solid tumours cause more harm than good? A systematic review

Jess Morgan, Ruth Walker, Melissa Harden, and Bob Phillips
jess.morgan@york.ac.uk @drjessmorgan

Methods

Standard systematic review methodology
PROSPERO CRD42018103764

13 databases, conference proceedings, and trial registries searched alongside reference lists and forward citations, from 1990 onwards.

Inclusion criteria:

- Patients up to age 25 who have completed treatment for malignant extra-cranial solid tumour
- Study evaluating a programme of routine surveillance imaging aiming to detect relapse
- High income countries only
- Quantitative or qualitative research

Exclusion criteria

- Patients with cancer predisposition syndromes
- Studies evaluating side effects of treatment

Risk of bias assessed using modified ROBINS-I

Included studies

n=55, 10,207 participants

Majority retrospective cohort, no RCTs

Moderate to high risk of bias in almost all studies

Patient and parent involvement in study

Mixed group of people: different cancer types, some had experience of relapse, some children had died.

Varied baseline opinions on whether surveillance imaging is a good idea or not.

Informed focus and design, interpretation and dissemination of systematic review

	No of studies (pts)	Evidence of survival benefit?	Harms?
Non-Hodgkin's lymphoma	4 (110)	✗	Lots of scans, high radiation dose, false positive images
Hodgkin's lymphoma	4 (693)	✗	Lots of scans, false positive images
Osteosarcoma	5 (247)	No data	Lots of scans
Ewing's sarcoma	4 (355)	?	No data
Wilm's tumour	6 (5057)	+	Lots of scans, high cost
Hepatoblastoma	3 (73)	No data	Lots of scans, AFP was better than scans
Neuroblastoma	5 (487)	✗	Lots of scans, high radiation dose
Retinoblastoma	2 (65)	No data	Lots of scans, false positive images
Soft tissue sarcoma	5 (560)	✗	Lots of scans

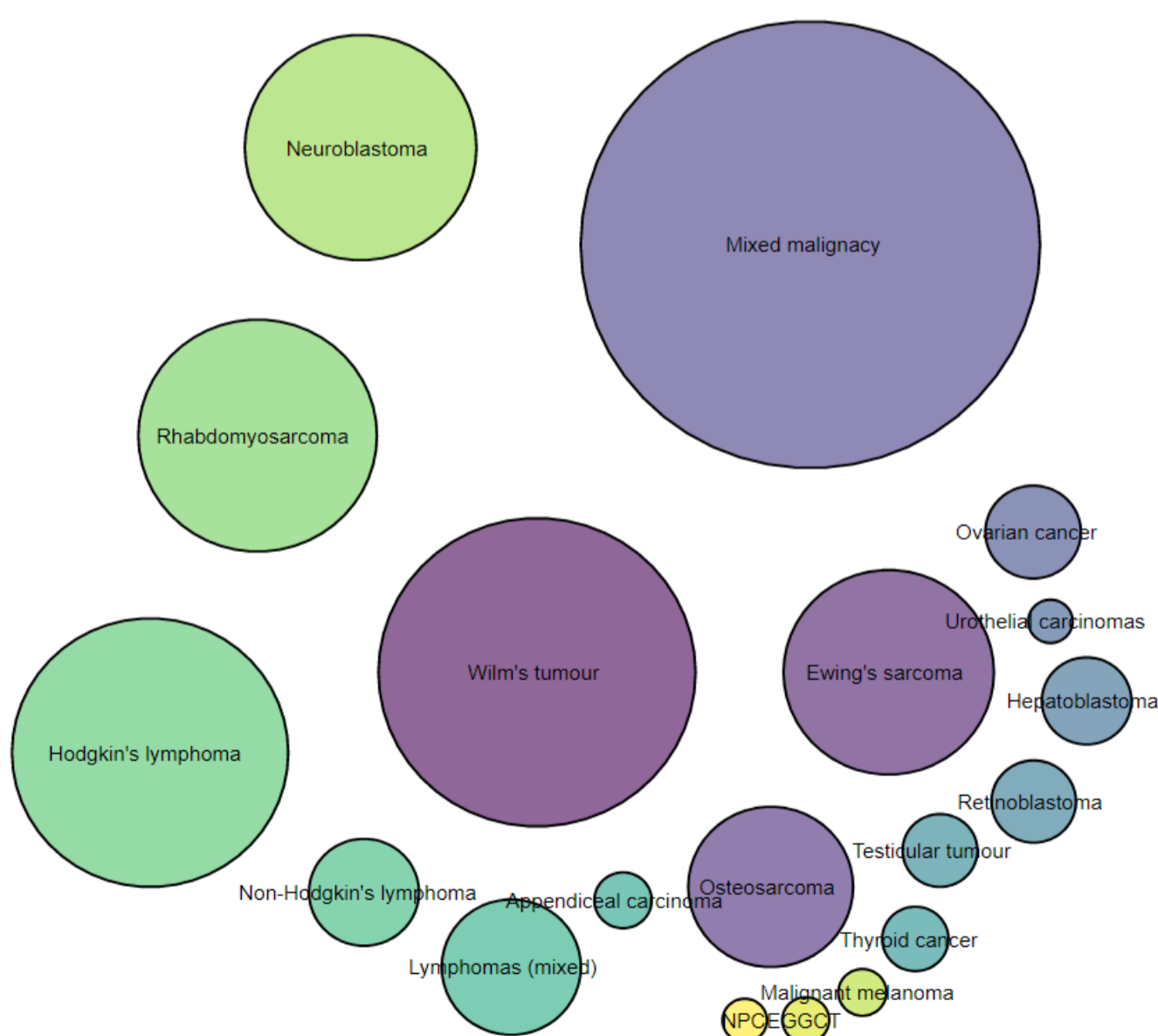


Figure: number of patients included with each tumour type

Key findings

- Paediatric surveillance strategies are varied, involve many scans and substantial radiation exposure
- For most tumours, surveillance imaging was not consistent with increased survival
- There is insufficient evidence to support routine surveillance imaging in most paediatric extra-cranial solid tumours
- The paediatric oncology community should focus on high quality RCTs and qualitative data to understand if routine surveillance imaging is doing more harm than good